

<b>Capsule Endoscopy Logbook (50 procedures)</b>							<b>Anonymous, colour scope marked with log book # provided</b>
<b>No</b>	<b>Date of study</b>	<b>Patient Age</b>	<b>Indication</b>	<b>Submit Complete Studies Only</b>	<b>Result</b>	<b>Abnormality</b>	
		Years	anaemia=A; PJS=P; Obscure bleeding=O; Other= Text	Views to colon Y=Yes; N=No	Normal = N Abnormal = Ab	vascular=V; inflammatory=I; neoplastic=N; polyp=P; other=Text	Indicate 10 abnormal cases with an "x"
1	19/11/2015	47	A	Y	Ab	V	
2	19/11/2015	79	A	Y	Ab	N	X
3	5/10/2015	79	A	Y	Ab	V	
4	18/05/2015	68	A	Y	Ab	Erosions, ulcers, red spots	X
5	17/05/2015	79	A	Y	N		
6	17/05/2015	60	A	Y	Ab	I	X
7	16/05/2015	82	A	Y	N		
8	15/05/2015	73	A	Y	Ab	N	
9	14/05/2015	73	A	Y	Ab	Other - nodule	X
10	13/05/2015	42	A	Y	N		
11	12/05/2015	82	A	Y	N		
12	4/02/2015	46	A	Y	N		
13	4/02/2015	58	A	Y	N		
14	4/02/2015	42	A	Y	Ab	Other - pus	X
15	1/02/2015	55	A	Y	N		
16	1/02/2015	56	A	Y	N		
17	1/02/2015	58	A	Y	N		
18	27/10/2014	60	A	Y	N		
19	27/10/2014	48	A	Y	Ab	V, I	
20	27/10/2014	56	A	Y	Ab	P	
21	27/10/2014	68	A	Y	Ab	I	X
22	27/10/2014	68	A	Y	N		
23	27/10/2014	65	A	Y	N		
24	27/10/2014	64	A	Y	N		
25	18/05/2014	72	A	Y	N		

<b>Capsule Endoscopy Logbook (50 procedures)</b>							<b>Anonymous, colour scope marked with log book # provided</b>
<b>No</b>	<b>Date of study</b>	<b>Patient Age</b>	<b>Indication</b>	<b>Submit Complete Studies Only</b>	<b>Result</b>	<b>Abnormality</b>	
		Years	anaemia=A; PJS=P; Obscure bleeding=O; Other= Text	Views to colon Y=Yes; N=No	Normal = N Abnormal = Ab	vascular=V; inflammatory=I; neoplastic=N; polyp=P; other=Text	Indicate 10 abnormal cases with an "x"
26	18/05/2014	79	A	Y	Ab	V	
27	18/05/2014	60	A	Y	Ab	I	X
28	18/05/2014	73	A	Y	Ab	Other - nodule	
29	18/05/2014	68	A	Y	Ab	I	X
30	18/05/2014	64	A	Y	N		
31	25/04/2014	68	A	Y	N		
32	25/04/2014	55	A	Y	N		
33	25/04/2014	46	A	Y	N		
34	25/04/2014	60	A	Y	N		
35	25/04/2014	65	A	Y	N		
36	25/04/2014	72	A	Y	N		
37	8/10/2013	47	A	Y	Ab	V	X
38	8/10/2013	48	A	Y	Ab	V, I	
39	8/10/2013	56	A	Y	N		
40	8/10/2013	58	A	Y	N		
41	8/10/2013	42	A	Y	N		
42	8/10/2013	82	A	Y	N		
43	11/07/2012	73	A	Y	N		
44	11/07/2012	79	A	Y	Ab	N	
45	11/07/2012	56	A	Y	Ab	P	
46	11/07/2012	58	A	Y	N		
47	11/07/2012	42	A	Y	Ab	Other - scalloped appearance	X
48	11/07/2012	82	A	Y	N		
49	23/06/2012	73	A	Y	Ab	N	
50	23/06/2012	79	A	Y	N		

## Capsule Endoscopy Report

---

XXXXXXXXXXXXXXXXXX	Name	
XXXXXXXXXXXXXXXXXX	ID	
XXXXXXXXXXXXXXXXXX	Date of birth	
XXXXXXXXXXXXXXXXXX	Age	68
	Gender	Female
	Doctor in charge	XXXXXXXXXXXXXXXXXX
	Reviewer	XXXXXXXXXXXXXXXXXX
	Procedure date	18/05/2015

---

### Reason for referral

Recurrent iron deficiency anaemia ? cause.

### Transit time

Total: 11 h 56 m, Small Bowel: 05 h 50 m, Colon: 05 h 48 m

### Procedure Info & Findings

Examination of the small bowel was complete to the caecum. An antral erosion was present. Several non-bleeding aphthous ulcers/erosions were noted at the mid small bowel. 2 tiny red spots were noted at the proximal and distal thirds of the small intestine.

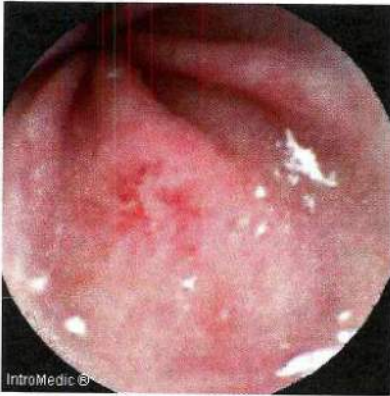### Summary & Recommendations

1. Antral erosion.
2. Small bowel red spots X 2. Significance of these is unclear as neither were big nor bleeding.
3. Mid small bowel erosions/ulcer - ? related to previous Brufen use. The other differential diagnosis includes Crohn's disease, but she has no diarrhoea, abdominal pain or haematochezia.

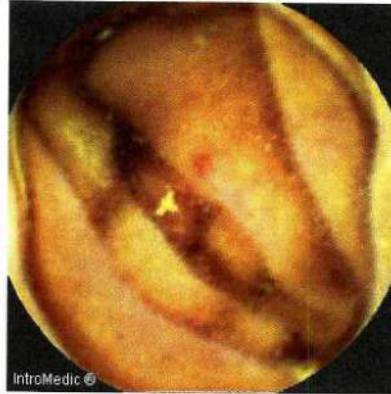Signature                     Your signature                    

---

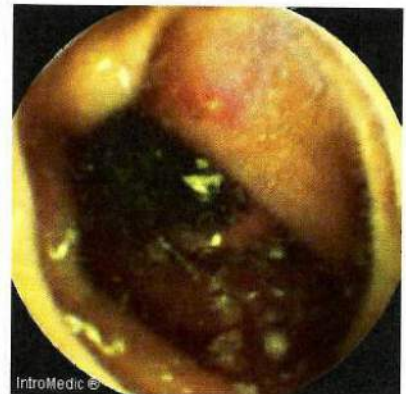Captured image



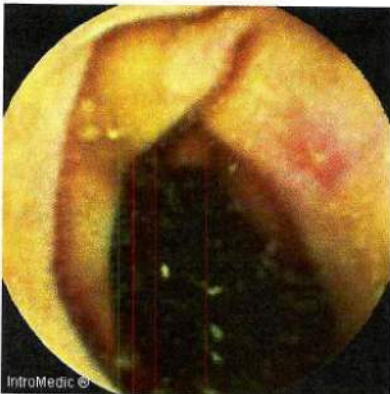
00:03:43  
Antral erosion.



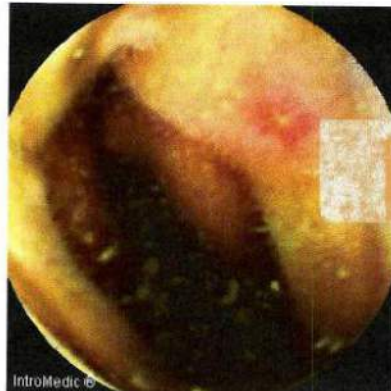02:40:11  
Red spot.



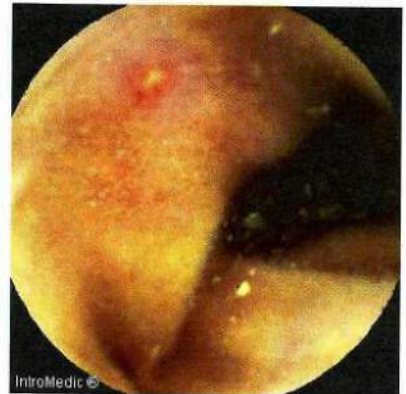02:55:20  
SB erosion.



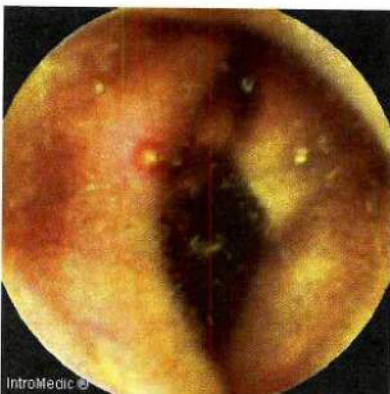02:57:12  
SB erosion.



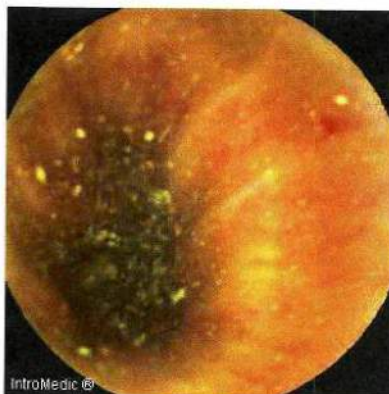02:57:55  
SB erosion.



03:00:28  
SB erosion.



03:37:19  
SB erosion.



05:43:30  
Red spot.